



Kharazmi University

Evaluating the effect of ozone in reducing the toxicity of corn contaminated with ochratoxinA in Wistar rats

Maryamsadat Mesbahi Bidgoli¹, Mohammad Fazilati¹, Anosheh Rahmani^{2✉}, Habibollah Nazem¹

1. Department of Biochemistry, Payame Noor University, P.O.Box 19395-4697, Tehran, Iran
E-mail: maryam.mesbahi@isfahan.pnu.ac.ir, mfazilati@pnu.ac.ir, h_nazem@pnu.ac.ir

2. Corresponding author, Department of Food, Halal and Agricultural Products, Food Technology and Agricultural Products Research Center, Standard Research Institute (SRI), Karaj, Iran. E-mail: a.rahmani@standard.ac.ir

Article Info

Article type:
Research Article

Article history:
Received 05 May 2025
Received in 28 September 2025
Accepted 27 September 2025
Available 01 September 2025

Keywords:
Biochemistry,
Fungi toxins,
Histopathology,
In vivo toxicity,
Wistar rat

ABSTRACT

Objective: Ozone treatment has been recognized as an effective approach to significantly reduce mycotoxin levels, including ochratoxin A (OTA), in agricultural products. This study aimed to evaluate the safety of untreated and ozone-treated OTA-contaminated corn (OCC) through a sub-chronic toxicity assessment in rats.

Method: Male rats were randomly assigned into one control group and three experimental diet groups. The experimental groups received untreated OCC or ozone-treated OCC through oral administration for a 30-day period. Clinical signs, survival, hematological parameters, serum biochemical indices, and histopathological alterations of liver and kidney tissues were examined to evaluate potential toxicological effects.

Results: No mortality or overt clinical abnormalities were observed during the experimental period. Rats fed untreated OCC exhibited significant decreases in white blood cell (WBC) counts and marked elevations in alanine aminotransferase (ALT), aspartate aminotransferase (AST), and alkaline phosphatase (ALP) levels. Histopathological evaluation revealed OTA-induced lesions in both liver and kidney tissues. In contrast, rats fed ozone-treated OCC showed reduced biochemical alterations and attenuated histopathological damage compared with those receiving untreated OCC.

Conclusions: These findings suggest that ozone treatment effectively diminishes the adverse effects of OTA contamination in corn, while exerting minimal toxicological impact on experimental animals. Ozone treatment may therefore serve as a practical and safe strategy to mitigate OTA-related health risks in agricultural products.

Cite this article: Mesbahi Bidgoli, M., Fazilati, M., Rahmani, A. & Nazem, H. (2025). Evaluating the effect of ozone in reducing the toxicity of corn contaminated with ochratoxinA in Wistar rats. *Nova Biologica Reperta*, 12 (2), 1-20. <http://doi.org/10.22034/NBR.12.2.7>



© The Author(s).

DOI: <http://doi.org/10.22034/NBR.12.2.7>

Publisher: Kharazmi University.

Introduction

Contamination of crops by mycotoxins is a worldwide challenge that causes great economic losses even with the implementation of efficient methods for agriculture, storage, and processing, these contaminants present a significant challenge to food safety (Alshannaq & Yu, 2017)

Mycotoxins are byproducts generated by certain species of fungi. Ochratoxin A (OTA) is among the most significant mycotoxins, generated by several species of *Penicillium* and *Aspergillus* (Bilgrami & Choudhary, 1998; Shinha & Bhatnagar, 1998). Ochratoxin A is a mild organic acid that has a molar mass of 403.8 g. mol⁻¹, characterized by a crystalline structure. This toxin, which is formed during the storage process of agricultural products, is one of the most common and toxic mycotoxins among other mycotoxins discovered so far (Malir, Ostry, Pfohl-Leszkowicz, Malir, & Toman, 2016). Ochratoxin A causes serious health problems such as nephrotoxicity, renal tumors, and carcinogenesis in both humans and animals (Romanelli et al., 2021).

Ochratoxin A, being a contributor to the contamination of food and animal feed, poses a risk to both human and animal health and also impacts individuals' access to food and nutrition. These toxins contaminate products both before and after harvest (Azizi, Rahimi, & Shateri, 2012). In recent years, the impact of these toxins on human health has been studied. Various studies have shown the relationship between OTA and the occurrence of human diseases like Chronic Interstitial Nephropathy and Balkan Endemic Nephropathy (Kosicki, Buharowska-Donten, & Twarużek, 2021; Nourbakhsh & Tajbakhsh, 2021). Due to the action of ochratoxin on kidney tissue, the induction of apoptosis through the amino-terminal kinase c-jun pathway leads to a teratogenic effect (Niaz, Shah, Khan, & Bule, 2020). The International Agency for Research on Cancer has categorized OTA as a human carcinogen, placing it in group 2B (Ortiz-Villeda, Lobos, Aguilar-Zuniga, & Carrasco-Sánchez, 2021). A study in Poland also demonstrated that OTA was detected in breast milk and it can pass through the human placenta into fetal blood (Ferrufino-Guardia, Chavez-Rico, & Larondele, 2019). Acceptable levels of ochratoxin A are 1 to 50 µg/kg for human food, and from 100 to 1000 µg/kg for animal feed (Chain et al., 2020). Due to the high prevalence of ochratoxin A contamination of grains and food, various methods have been investigated to reduce the amount of ochratoxin A to preserve the value of food products and prevent possible harm to human and animal health. The management of agricultural products after harvest, to improve food safety, encompasses detoxification methods designed to eliminate or diminish the presence of ochratoxin A (Risk Assessment of Ochratoxin A in Food | EFSA, 2020). In many instances, the methods explored for the degradation of mycotoxins relied on traditional techniques, including thermal treatments. However, these techniques were not able to eliminate these contaminants while still maintaining the properties of the food.

Various processes have been investigated to reduce OTA contamination, such as high-temperature roasting, canning, alkaline cooking, and extrusion (Rodríguez & Núñez, 2020). In all these processes, the use of high temperatures is required, which may cause damage to the nutritional value of the grain (Mondani et al., 2020). OTA is a chemically stable substance that exhibits considerable resistance to both acidic conditions and elevated temperatures. Consequently, once food products become contaminated, complete detoxification proves to be quite challenging (Li, Ma, Ma, Zhang, & Li, 2022).

Therefore, advanced methods are used to identify, diagnose, and reduce their adverse effects. In recent years, one of the methods that has received attention is exposing grains to ozone. Ozone has been demonstrated to be significant in the breakdown of OTA from agricultural

products, serving as a safe, effective, and environmentally sustainable processing technique (“Ochratoxin A: Occurrence and Recent Advances in Detoxification,” 2022). Ozone gas possesses potent oxidizing characteristics and significant permeability, enabling it to interact with functional groups present in mycotoxin molecules. This interaction can alter their molecular structure, resulting in products that exhibit reduced molecular weight, fewer double bonds, and diminished toxicity. The current research seeks to assess the safety of OTA-contaminated corn (OCC) that has been treated with ozone, utilizing a sub-chronic toxicity study involving rats.

Method

Sample preparation

Both OTA-contaminated corn (OCC) and uncontaminated corn were obtained from Brazilian imports to Iran in late June 2022. OCC samples were stored at 4 °C until use. Specialized feed was prepared by grinding corn kernels and mixing the powder with water in a 3:1 ratio to formulate the daily diet for the rats.

Ozone treatment

Ozone was generated using the MOG002 Ozone Generator (O3 Tech H.K Limited, Shenzhen, China). OCC samples were exposed to 600 mg/kg of ozone for 240 minutes, a condition previously identified as optimal for maximum mycotoxin reduction (Rahmani, Hajihosseini, & Mahmoudi-Meymand, 2024). The corn was placed in a sealed cylindrical steel reactor and treated with ozone gas. After treatment, the samples were transferred to sterile, labeled plastic bags and stored at 4 °C until further analysis and animal feeding.

Uncontaminated corn powder was divided into two portions: one for feeding the control group and the other subjected to ozonation for the ozonized control group. Naturally contaminated corn samples were finely ground and further spiked with an OTA solution to achieve a standardized concentration of 200 µg/kg, and homogenized. This ensured consistency across batches. The OCC was then divided into two portions: one for feeding the OCC group and the other ozonized for the ozonized OCC group.

Determination of ochratoxin A

OTA levels were analyzed using reverse-phase high-performance liquid chromatography (HPLC; Agilent Technologies, Palo Alto, CA, USA) equipped with a fluorescence detector. The excitation and emission wavelengths were set at 333 and 477 nm, respectively, following Iran National Standard No. 9238 with minor modifications (Skarkova, Ostry, Malir, & Roubal, 2013). Chromatographic separation was performed using an Agilent ZORBAX SB-C18 column (150 × 4.6 mm, 5 µm).

For extraction, 25 g of sample was mixed with 100 ml of acetonitrile–water (84:16, v/v) in a 250 ml Erlenmeyer flask, shaken for 3 min, filtered through Whatman filter paper, and purified using an immunoaffinity column. Ten milliliters of the filtrate were diluted with 50 ml phosphate-buffered saline (PBS) and filtered through GF paper. Columns were conditioned with 10 ml PBS before loading 55 ml of the diluted extract at a flow rate of 2–3 ml/min. After rinsing with 10 ml PBS and drying under positive air pressure, OTA was eluted with 1.5 ml of methanol–acetic acid (98:2, v/v) into an amber vial. The eluate was diluted with 1.5 ml deionized water, vortexed, and 20 µl of the final extract was injected into the HPLC. OTA concentrations were quantified by comparing peak areas with calibration standards (0.5–20 µg/ml; $r = 0.996$).

Animals and study design

Nine-week-old male Wistar rats (≈ 250 g) were obtained from the Pasteur Institute of Iran. Animals were housed under controlled conditions (22–24 °C, $45 \pm 10\%$ humidity, 12 h light/dark cycle). All protocols were approved by the Ethical Committee of Animal Experiments at Payame Noor University of Medical Sciences (Project code: IR.PNU.REC.1403.223).

Experimental design

After acclimatization, 24 rats were randomly assigned to four groups ($n = 6$ per group) and maintained for one month to assess sub-chronic toxicity. Each rat received 20 g of diet daily:

1. Control group: uncontaminated corn
2. Ozonized control group: ozone-treated uncontaminated corn
3. OCC group: OTA-contaminated corn (200 $\mu\text{g}/\text{kg}$)
4. Ozonized OCC group: ozone-treated OTA-contaminated corn (8 $\mu\text{g}/\text{kg}$)

OTA was not detected in the control and ozonized control diets.

Hematological, biochemical, and histopathological analysis

At the end of the study, rats were fasted for ≥ 12 h before blood collection. Under light diethyl ether anesthesia, blood was collected via retro-orbital puncture and the animals were subsequently euthanized.

- Hematology: Blood samples were collected in EDTA tubes, homogenized on a roller mixer for 15 min, and analyzed for WBC, RBC, and HGB using a Sysmex KX21 cell counter.

- Biochemistry: Serum was analyzed using an automated analyzer (Roche Cobas C501; Roche Group, Switzerland) for ALT, AST, ALP, urea, creatinine, glucose, and cholesterol, triglycerides (TG), HDL, and LDL.

- Histopathology: Liver and kidney tissues were excised, rinsed in cold saline, and fixed. Sections (5 μm) were prepared from paraffin-embedded samples, stained with hematoxylin–eosin, and examined microscopically (Leica DM2000; Bensheim, Germany (Diao, Hou, Chen, Shan, & Dong, 2013; S. Luo, Du, Kebede, Liu, & Xing, 2021; X. Luo et al., 2018)).

Statistical analysis

All experiments were performed in triplicate, and results are presented as mean \pm standard deviation. Statistical analyses were performed using MINITAB version 19. One-way ANOVA was applied for comparisons among groups, and Tukey's HSD post-hoc test was used for multiple comparisons following ANOVA (replacing independent t-tests). A p -value < 0.05 was considered statistically significant.

Results

The analysis of variance (ANOVA) revealed statistically significant differences in serum biochemical and hematological parameters among the four experimental groups ($p < 0.05$). The optimized ozone treatment (600 mg/kg for 240 min at room temperature) reduced OTA levels in corn from 200 $\mu\text{g}/\text{kg}$ to 8 $\mu\text{g}/\text{kg}$, corresponding to more than a 96% reduction.

Biochemical analysis

Biochemical analysis (Table 1) showed that rats in the OTA-contaminated corn (OCC) group exhibited significantly higher activities of ALT, AST, and ALP compared with the control groups ($p < 0.05$). Among the four groups, only the OCC group had values exceeding the normal ranges of ALT (18–45 U/L), AST (74–143 U/L), and ALP (62–230 U/L). In the ozonized OCC

group, ALT and AST values remained within normal limits, while ALP showed a slight elevation. These findings suggest that ozone treatment significantly mitigated OTA-induced hepatotoxicity.

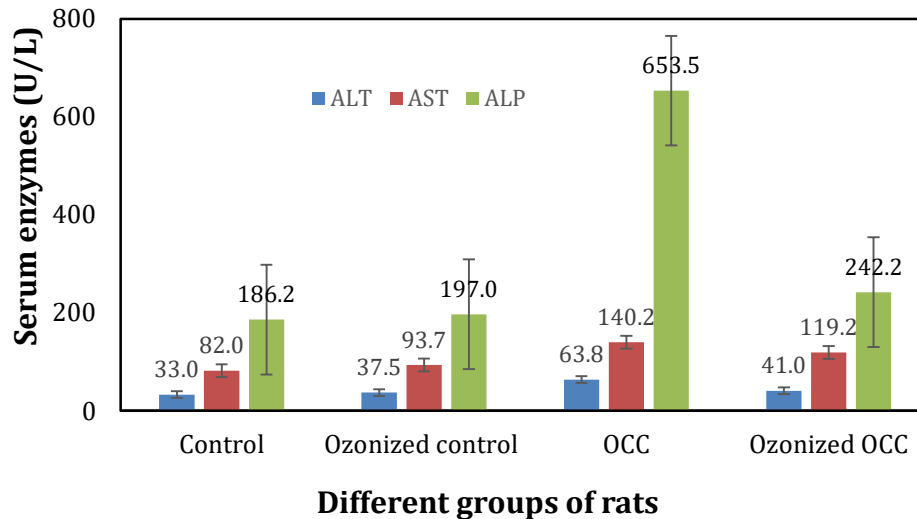


Figure 1. Serum ALT, AST, and ALP liver enzymes activity un-contaminated and OTA contaminated corn (OCC) and ozonized groups. Values are expressed as mean \pm SD (n=6).

Table 1. Serum liver enzyme activities (ALT, AST, ALP) in rats fed with different corn diets. Data are presented as mean \pm SD (n=6). *p < 0.05 compared to control.

| | Groups | | Rats | |
|--------------------|---------|---------|---------|---------|
| | F-value | P-value | F-value | P-value |
| ALT | 19.02 | 0.000 | 0.63 | 0.682 |
| AST | 17.8 | 0.000 | 0.44 | 0.816 |
| ALP | 11.15 | 0.000 | 1.19 | 0.359 |
| Urea | 56.42 | 0.000 | 1.02 | 0.441 |
| Creatinine | 7.44 | 0.003 | 0.45 | 0.809 |
| Glucose | 0.65 | 0.594 | 0.38 | 0.851 |
| Cholesterol | 0.16 | 0.925 | 0.21 | 0.953 |
| TG | 17.45 | 0.000 | 2.13 | 0.118 |
| LDL | 3.04 | 0.061 | 0.36 | 0.869 |
| HDL | 4.28 | 0.023 | 1.04 | 0.432 |

Serum levels of urea and creatinine, which are indicators of renal function, are presented in Table 2. Both markers were significantly elevated in the OCC group, surpassing the normal reference ranges. In contrast, mean values in the control and ozonized control groups remained within normal ranges, whereas the ozonized OCC group showed only slight increases. This demonstrates that ozonation alleviates OTA-induced nephrotoxicity.

Table 2. Serum urea and creatinine concentrations in rats fed with different corn diets. Data are presented as mean \pm SD (n=6). Different superscript letters (a, b, c) indicate statistically significant differences among groups based on Tukey's HSD post-hoc test ($p < 0.05$).

| GROUP | Analysis of Biochemistry Data in the Study Groups | | | | | | |
|------------------|---|-------------------|-------------------|------------------|----------------------|---------------------|---------------------|
| | Urea | Creatinine | Glucose | Cholesterol | TG | LDL | HDL |
| Control | 20.5 \pm 1.4 a | 0.43 \pm 0.08a | 191.7 \pm 8a | 66.2 \pm 15.7a | 96.7 \pm 7.9 c | 22 \pm 4.4a | 22.2 \pm 5.4 a |
| Ozonized Control | 19.3 \pm 1.2 a | 0.43 \pm 0.08a | 193.5 \pm 11.7a | 61.8 \pm 16.4a | 77.3 \pm 3.4 a | 21.5 \pm 1.8 a | 31.7 \pm 6.2 a |
| OCC | 45.2 \pm 4.9 b | 0.61 \pm 0.07 b | 181.3 \pm 11.9a | 61.2 \pm 5.7a | 84 \pm 3 b | 21.2 \pm 1.5 a | 32.5 \pm 5.9 a |
| Ozonized OCC | 24.2 \pm 5.9 a | 0.51 \pm 0.01a | 189.5 \pm 23.6a | 62 \pm 9.9a | 94.5 \pm 7.9 bc | 25.8 \pm 2.2 a | 31.6 \pm 5.7 a |
| Normal Range | 12.3-24.6 | 0.2-0.5 | 70-208 | 37-85 | 20-114 | 100> | 40> |

The analysis of lipid and carbohydrate metabolism revealed no significant differences in glucose, cholesterol, HDL, or LDL levels among the groups. However, triglyceride (TG) levels were significantly higher in the OCC group compared with the other groups ($p < 0.05$).

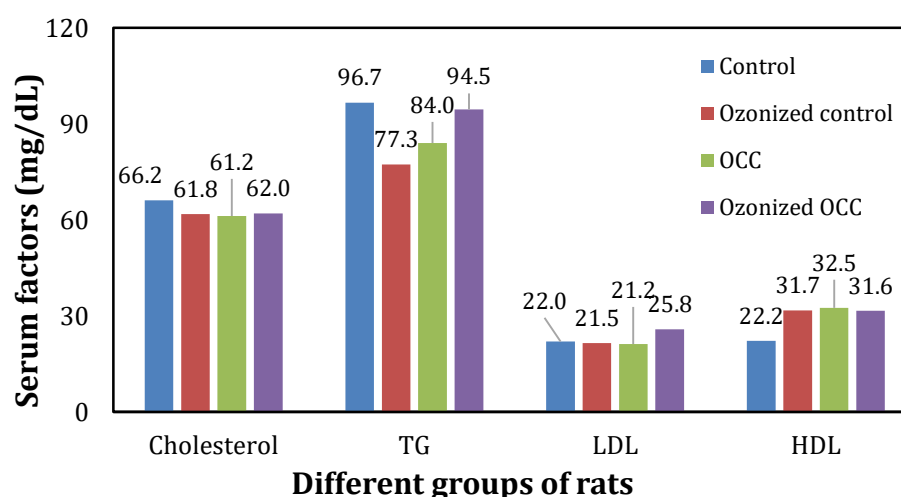


Figure 2. Serum cholesterol, TG, LDL and HDL of un-contaminated and OTA contaminated corn (OCC) and ozonized groups

Hematological analysis

Hematological data (Table 3) indicated that WBC counts were significantly elevated in rats fed with OCC compared to other groups ($p < 0.05$). In the ozonized OCC group, WBC counts were slightly increased compared with the control groups, but this difference was not statistically significant. Lymphocyte and monocyte counts did not differ significantly among groups. Other hematological indices, including RBC, HGB, HCT, MCV, MCHC, RDWCV, PLT, and eosinophils, showed no notable changes.

Table 3. Hematological parameters of rats fed with different corn diets. Data are presented as mean \pm SD (n=6).

| | Groups | | Rats | |
|--------------------|---------|---------|---------|---------|
| | F-value | P-value | F-value | P-value |
| WBC | 9.24 | 0.001 | 1.29 | 0.321 |
| Granulocyte | 1.07 | 0.392 | 0.88 | 0.519 |
| Lymphocyte | 1.22 | 0.338 | 0.73 | 0.614 |
| Monocyte | 1.48 | 0.259 | 0.44 | 0.816 |
| Eosin | 2.51 | 0.098 | 0.75 | 0.598 |
| RBC | 2.42 | 0.106 | 0.28 | 0.916 |
| HGB | 2.32 | 0.116 | 0.74 | 0.607 |
| HCT | 2.66 | 0.085 | 0.78 | 0.581 |
| MCV | 1.07 | 0.392 | 1 | 0.453 |
| MCHC | 1.29 | 0.315 | 0.65 | 0.666 |
| RDWCV | 3.19 | 0.054 | 5.16 | 0.669 |
| PLT | 2.3 | 0.119 | 0.96 | 0.47 |

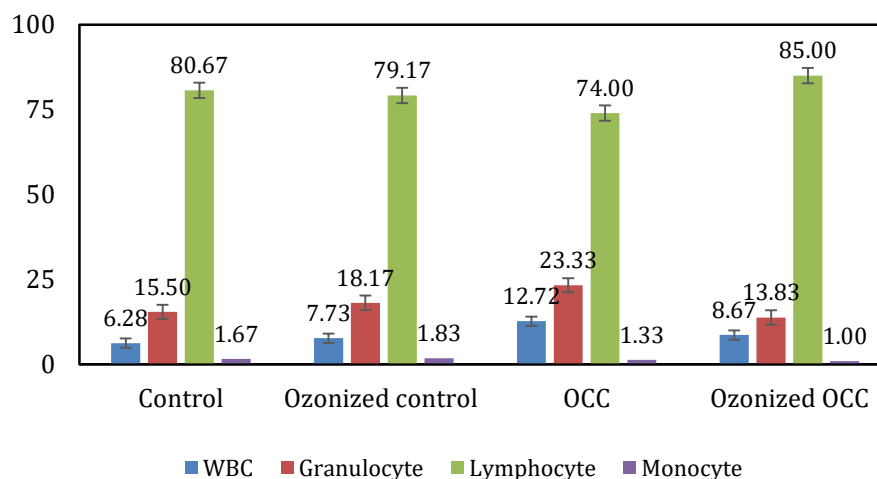


Figure 3. WBC counts in experimental groups. Values are expressed as mean \pm SD (n=6). * $p < 0.05$ compared to control.

Histopathological analysis

Histopathological evaluation of liver and kidney tissues corroborated the biochemical and hematological results. No pathological alterations were detected in the control and ozonized control groups (Figures 4 and 5). In contrast, the OCC group showed severe hepatic vacuolar degeneration, sinusoidal contraction, and marked necrosis, while kidney tissues exhibited extensive tubular necrosis, karyolysis, hemorrhage, and edema (Figure 6). Importantly, the ozonized OCC group displayed no significant liver damage and only mild renal alterations, including focal tubular necrosis, karyolysis, minor hemorrhage, and mild glomerular collapse (Figure 7).

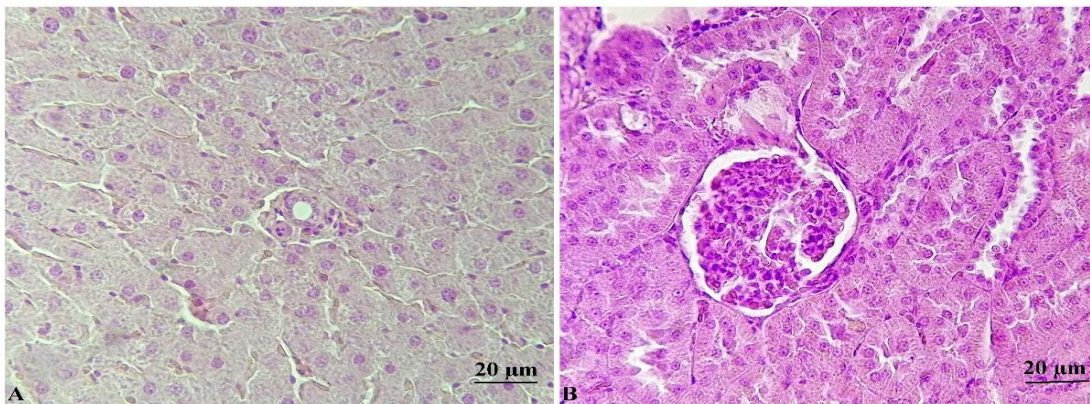


Figure 4. Normal histological appearance in the control group: (A) liver and (B) kidney.

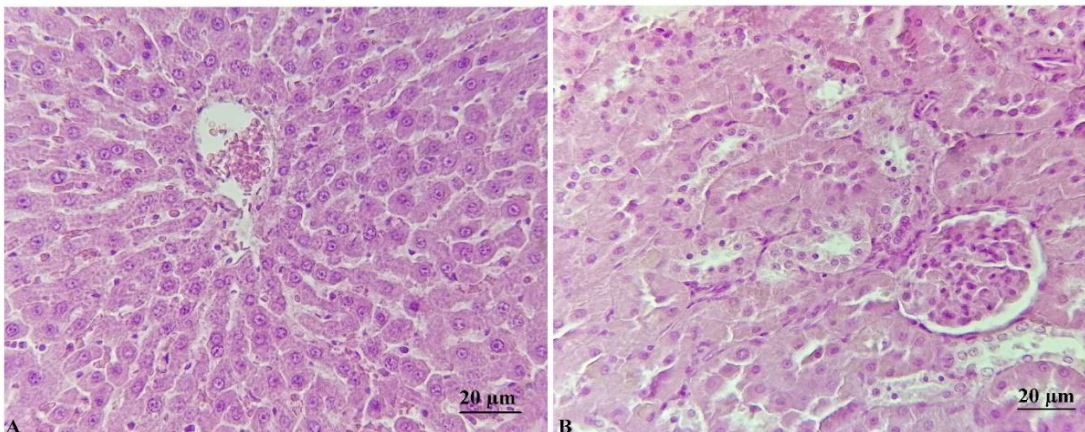


Figure 5. Histological appearance of the liver (A) and kidney (B) from rats fed with ozonized uncontaminated corn (ozonized control group). Both organs show normal findings.

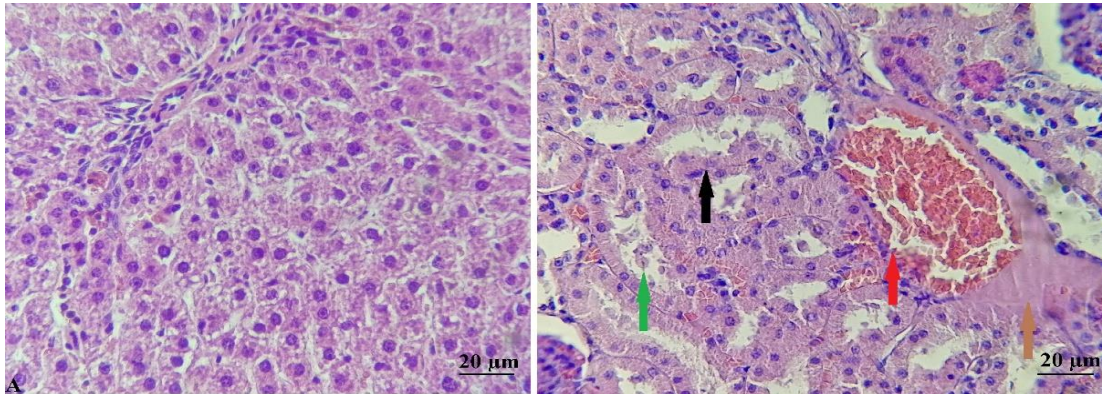


Figure 6. Liver and kidney histology from rats fed with OTA contaminated corn (OCC)

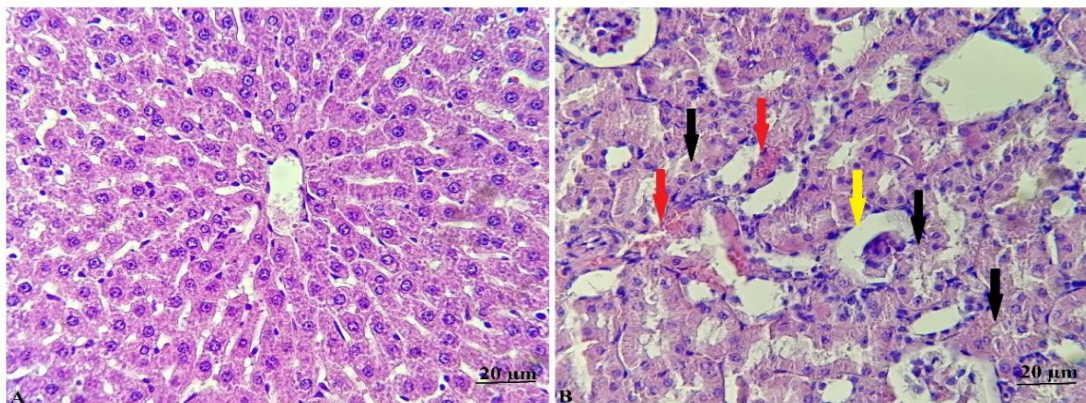


Figure 7. Liver and kidney histology from rats fed with ozonized OTA contaminated corn (ozonized OCC)

Discussion

The present study demonstrates that ozone treatment significantly reduces OTA contamination in corn and its associated toxic effects *in vivo*. Under optimized conditions (600 mg/kg ozone for 240 minutes), OTA concentrations were reduced by more than 96%, from 200 µg/kg to 8 µg/kg. These results align with previous studies that reported variable detoxification efficiencies depending on ozone concentration, exposure duration, and environmental factors such as moisture and relative humidity (Afsah-Hejri, Hajeb, & Ehsani, 2020; Krstović, Krulj, Jakšić, Bočarov-Stančić, & Jajić, 2021; Torlak, 2019; Yang et al., 2020). Although higher ozone doses and longer exposure times enhance detoxification efficiency, they may negatively affect corn quality (Qi et al., 2016).

Biochemical and histopathological findings confirmed that OTA induces hepatotoxicity and nephrotoxicity. Rats exposed to untreated OCC showed elevated liver enzymes, abnormal renal function markers, and severe tissue lesions. In contrast, ozone treatment significantly attenuated these effects, with enzyme levels and tissue structures approaching those of controls. However, the slight increases in enzyme activity and mild kidney alterations observed in the ozonized OCC group suggest that residual OTA, though minimal, may still exert minor toxic effects.

These findings are consistent with earlier research showing that ozone treatment effectively reduces the toxicity of AFB1 and other mycotoxins, thereby preventing pathological alterations

in the liver and kidneys of exposed animals (Diao et al., 2013; Eshak, Deabes, Farrag, Farag, & Stino, 2013; Shivasharanappa, Mundas, Rao, Tikare, & Shridhar, 2013). Mechanistically, ozone likely attacks the phenylalanine moiety and/or the lactone ring of OTA, leading to cleavage and detoxification (Qi et al., 2016; Yang et al., 2020). Taken together, the evidence suggests that ozone treatment is a practical and effective approach for detoxifying OTA-contaminated agricultural products, substantially reducing associated health risks without imposing significant adverse effects on animal health.

Conclusions

The findings of this study clearly demonstrate the efficacy of ozone treatment in reducing OTA contamination and mitigating its toxic effects *in vivo*. Optimized ozonation conditions (600 mg/kg for 240 minutes) effectively reduced OTA concentration by more than 96%, in agreement with earlier reports that emphasized the influence of ozone concentration, exposure time, product moisture, and relative humidity on detoxification efficiency (Afsah-Hejri et al., 2020; Krstović et al., 2021; Torlak, 2019; Yang et al., 2020). Although higher doses and prolonged exposure times increase OTA detoxification, they may adversely affect corn quality (Qi et al., 2016). Biochemical and histopathological results demonstrated that OTA exposure caused significant hepatotoxicity and nephrotoxicity, as evidenced by elevated serum enzyme levels, impaired renal markers, and severe tissue lesions. Ozone treatment markedly reduced these adverse effects, restoring biochemical parameters and tissue structures to near-control levels. The slight increases in enzyme activities and mild renal lesions observed in the ozonized OCC group are likely attributable to residual OTA. These results are consistent with previous studies reporting that ozone treatment attenuates the toxicity of other mycotoxins, such as aflatoxin B1 (AFB1), by protecting liver and kidney function (Diao et al., 2013; Eshak et al., 2013; Shivasharanappa et al., 2013). Collectively, the evidence suggests that ozone treatment provides an effective and practical approach for detoxifying OTA-contaminated corn, substantially reducing health risks without introducing additional toxicological concerns.

Author Contributions

Conceptualization, Maryamsadat Mesbahi Bidgoli and Anosheh Rahmani; methodology, Maryamsadat Mesbahi Bidgoli and Mohammad Fazilati; software, Mohammad Fazilati; validation, Maryamsadat Mesbahi Bidgoli, Habibollah Nazem, and Anosheh Rahmani; formal analysis, Maryamsadat Mesbahi Bidgoli; investigation, Maryamsadat Mesbahi Bidgoli and Mohammad Fazilati; resources, Anosheh Rahmani; data curation, Mohammad Fazilati and Habibollah Nazem; writing original draft preparation, Maryamsadat Mesbahi Bidgoli; writing review and editing, Anosheh Rahmani and Habibollah Nazem; visualization, Mohammad Fazilati; supervision, Anosheh Rahmani; project administration, Anosheh Rahmani; funding acquisition, Anosheh Rahmani.

All authors have read and agreed to the published version of the manuscript. All authors contributed equally to the conceptualization of the article and writing of the original and subsequent drafts.

Data Availability Statement

Data available on request from the authors.

Acknowledgements

This study received financial backing from the dedicated research fund entitled “Investigation of Effective Factors and Optimization of Ozonation Method for Decontamination or Mitigation of Mycotoxins in Corn and Risk Assessment of Process byproducts” by Standard Research Institute (SRI) of Iran, received from Farhikhtegan Zar Research Industrial Group, Iran, under the supervision The Biotechnology Development Headquarters of the Vice Presidency for Science, Technology, and Knowledge-Based Economy in Iran. (Agreement No. 98/11601) – code, 476758).

The authors are grateful to Dr. Mehdi and Mohsen Amini for providing the technical infrastructure of the research, Dr. Bahar Borhani for cooperation in the ozonation process, and Dr. Masoumeh Mahmoudi-Meymand for testing other mycotoxins.

Ethical Considerations

The study was approved by the Ethics Committee of the University of ABCD (Ethical code: IR.UT.RES.2024.500).

Conflict of Interest

The authors declare no conflict of interest.

References

- Alshannaq, A., & Yu, J.-H. (2017). Occurrence, toxicity, and analysis of major mycotoxins in food. *International journal of environmental research and public health*, 14(6), 632 .
- Azizi, I. G., Rahimi, K., & Shateri, S. (2012). Ochratoxin: contamination and toxicity (A review). *Global Veterin*, 8, 519-524 .
- Bilgrami, K. S., & Choudhary, A. K. (1998). Mycotoxins in preharvest contamination of agricultural crops. In *Mycotoxins in agriculture and food safety* (pp. 19-62): CRC Press.
- Chain, E. P. o. C. i. t. F., Schrenk, D., Bodin, L., Chipman, J. K., del Mazo, J., Grasl-Kraupp, B., . . . Nebbia, C. S. (2020). Risk assessment of ochratoxin A in food. *EFSA journal*, 18(5), e06113 .
- Diao, E., Hou, H., Chen, B., Shan, C., & Dong, H. (2013). Ozonolysis efficiency and safety evaluation of aflatoxin B1 in peanuts. *Food and Chemical Toxicology*, 55, 519-525 .
- Ferruffino-Guardia, E., Chavez-Rico, V., & Larondelle, Y. (2019). Ochratoxin a in human breast milk, maternal and placental blood from Cochabamba-Bolivia. *Revista de Toxicología*, 36(2), 116-125 .
- Kosicki, R., Buharowska-Donten, J., & Twarużek, M. (2021). Ochratoxin A levels in serum of Polish dialysis patients with chronic renal failure. *Toxicon*, 200, 183-188 .

- Li, X., Ma, W., Ma, Z., Zhang, Q., & Li, H. (2022). Recent progress in determination of ochratoxin a in foods by chromatographic and mass spectrometry methods. *Critical reviews in food science and nutrition*, 62(20), 5444-5461 .
- Luo, S., Du, H., Kebede, H., Liu, Y., & Xing, F. (2021). Contamination status of major mycotoxins in agricultural product and food stuff in Europe. *Food Control*, 127, 108120 .
- Luo, X., Li, K., Xing, J., Qi, L., Yang, M., Wang, R., . . . Chen, Z. (2018). In vivo toxicity assessment of aflatoxin B1-contaminated corn after ozone degradation. *Food Additives & Contaminants: Part A*, 35(2), 341-350 .
- Malir, F., Ostry, V., Pfohl-Leszkowicz, A., Malir, J., & Toman, J. (2016). Ochratoxin A: 50 years of research. *Toxins*, 8(7), 191 .
- Mondani, L., Palumbo, R., Tsitsigiannis, D., Perdakis, D., Mazzoni, E., & Battilani, P. (2020). Pest management and ochratoxin A contamination in grapes: A review. *Toxins*, 12(5), 303 .
- Niaz, K., Shah, S. Z. A., Khan, F., & Bule, M. (2020). Ochratoxin A-induced genotoxic and epigenetic mechanisms lead to Alzheimer disease: Its modulation with strategies. *Environmental Science and Pollution Research*, 27(36), 44673-44700 .
- Nourbakhsh, F., & Tajbakhsh, E. (2021). Neurotoxicity mechanism of Ochratoxin A. *Quality Assurance and Safety of Crops & Foods*, 13(2), 34-45 .
- Ortiz-Villeda, B., Lobos, O., Aguilar-Zuniga, K., & Carrasco-Sánchez, V. (2021). Ochratoxins in wines: A review of their occurrence in the last decade, toxicity, and exposure risk in humans. *Toxins*, 13(7), 478 .
- Rahmani, A., Hajihosseini, R., & Mahmoudi-Meymand ,M. (2024). Optimization of Ozonation Method for Reduction of Aflatoxin B1 in Ground Corn and its Impact on other mycotoxins. *Journal of Food and Bioprocess Engineering*, 7(1) .
- Rodríguez, M., & Núñez, F. (2020). Novel approaches to minimizing mycotoxin contamination. In (Vol. 12, pp. 216): MDPI.
- Romanelli, M. A., Soeiro, P. A., da Silva, R. C., Taveira-da-Silva, R., Melo, P. A., & Lara, L. S. (2021). Revisiting the acute kidney injury in Wistar rats experimentally envenomated with Bothrops jararacussu venom. *Toxicon*, 199, 117-126 .
- Shinha, K. K., & Bhatnagar, D. (1998). *Mycotoxins in agriculture and food safety*: CRC Press.
- Skarkova, J., Ostry, V., Malir, F., & Roubal, T. (2013). Determination of ochratoxin A in food by high performance liquid chromatography. *Analytical Letters*, 46(10), 1495-1504 .

